
The Treatment of Articular Cartilage Defects Using the Microfracture Technique

Thomas J. Gill, MD¹

Peter D. Asnis, MD²

Eric M. Berkson, MD³

Chondral defects of the articular surface pose a challenging problem to the orthopedic surgeon. The goal of surgery is to alleviate pain, maximize function, and prevent degenerative changes in the future. A number of techniques have been described to treat these lesions. When considering the treatment options for chondral defects, the surgeon must consider the size, depth, location, and chronicity of the lesion. In addition, the overall alignment of the joint must be evaluated. Prior to treating chondral defects, it is important to understand the indications and contraindications for the microfracture technique. When indicated, the microfracture technique has many advantages over other surgical options. This technique is relatively easy to perform, cost effective, and has low patient morbidity. In addition, the microfracture technique does not burn any long-term bridges, enabling the surgeon to choose a different procedure to revise the chondral defect if the microfracture fails. It is important to understand the mechanism of healing by microfracture, including the effects of the local environment. The postoperative protocol used after the procedure may be as important as the surgery itself. Understanding the science behind the microfracture procedure will lead to better surgical technique and improved outcomes. *J Orthop Sports Phys Ther* 2006;36(10):728-738. doi:10.2519/jospt.2006.2444

Key Words: bone, knee, patellofemoral joint, tibiofemoral joint

The goals of surgery when treating chondral defects are to alleviate pain, maximize function, and prevent further degenerative changes. A number of open and arthroscopic techniques have been described for the treatment of these lesions. Among these techniques are arthroscopic debridement with chondroplasty, as well as “marrow stimulation techniques” such as abrasion arthroplasty (arthroscopic debridement of the base of the lesion down to bleeding bone), drilling (penetration of the subchondral plate using a drill), and microfracture. The advantages of these techniques include technical simplicity, low patient morbidity, and cost effectiveness. However, critics of these techniques argue that any clinical improvements obtained from these procedures are transient and that the repair tissue generated is largely fibrous in nature, with poor durability. When considering a first line of surgical treatment for a chondral defect, it is important to choose a procedure that is relatively easy to perform, cost effective, and has low patient morbidity. In addition, the surgeon should choose a procedure that has a high long-term clinical success rate, without “burning any long-term bridges” by jeopardizing the ability to perform future procedures.

¹ Associate Professor of Orthopaedic Surgery, Harvard Medical School, Boston, MA.

² Instructor in Orthopaedic Surgery, Harvard Medical School, Boston, MA.

³ Clinical Associate in Orthopaedic Surgery, Massachusetts General Hospital, Boston, MA.

Address correspondence to Thomas J. Gill, Sports Medicine Service, Massachusetts General Hospital, 55 Fruit Street, Yawkey 3G, Boston, MA 02114. E-mail: tgill@partners.org

Superficial Versus Full-Thickness Defects

The body's response to a chondral injury depends on the depth of the lesion. The healing cascade stimulated by a full-thickness chondral defect is different from that of superficial lesion. While there have been several reports that superficial lesions have the ability to heal,^{5,6,32} more recent investigations have refuted this concept.^{10,30,35,38} A brisk reparative process is stimulated in the first several weeks following superficial injury. However, the reparative process diminishes with time and does not show evidence of repair over longer periods of observation.³⁵ It is currently accepted that defects of the cartilage structure are not replaced unless the subchondral plate has been breached.^{30,38} The true importance of partial-thickness chondral lesions is a source of debate. There is evidence that superficial injuries are limited in progression and do not lead to clinical osteoarthritis.^{35,36,42,53}

Capacity of Full-Thickness Articular Cartilage Defects to Heal

For hundreds of years, it has been known that chondral injuries represent a difficult clinical problem. In 1743, Hunter wrote, “From Hippocrates to the present age, it is universally allowed that

ulcerated cartilage is a troublesome thing and that when once destroyed it is not repaired."¹¹ In 1851, Sir James Paget wrote, "There are, I believe, no instances in which a lost portion of cartilage has been restored, or a wounded portion repaired, with new and well-formed permanent cartilage, in the human subject."⁴¹ These conclusions have been supported by more recent investigations that have shown that articular cartilage has no blood, nerve, or lymphatic supply.³⁴ Furthermore, articular cartilage has virtually no potential for repair, especially in the mature animal.³⁴

However, after the chondral surface is injured, articular chondrocytes are metabolically active. Protein polysaccharides are synthesized and degraded at a rate that is too rapid to be entirely explained by the minimal attritional loss incurred by articular cartilage. Thus, it is likely that there is an active internal remodeling system whose level of activity is dependent on the surrounding environment.³⁴ The synthetic activity of DNA appears to cease with maturity and the development of the calcified zone and tidemark.³⁵ DNA synthesis for cartilage production resumes under specific conditions such as acromegaly, osteoarthritis, mild compression, and lacerative injury. Unfortunately, this response is limited, and is not sufficient to heal chondral defects or areas of osteoarthritis.³⁵

In 1851, Redfern discussed the potential for articular cartilage to heal when he stated, "I no longer contain the slightest doubt that wounds in articular cartilage are capable of perfect union by the formation of fibrous tissue out of the texture of the cut surfaces."^{43,44} Unfortunately, "fibrous tissue" and "fibrocartilage" contain a high proportion of type I collagen, while the properties of the articular cartilage are determined by the matrix macromolecules. Type II collagen gives cartilage its form, tensile stiffness, and strength. Type IX collagen helps to organize the meshwork of type II collagen fibrils.⁴ The question remains whether surgically treated lesions of articular cartilage heal with hyaline cartilage, an altered form of hyaline cartilage, or with fibrocartilage. Each type of cartilage has different mechanical properties and, thus, different ability to yield good long-term results in terms of filling in chondral defects and maintaining structural integrity of the joint.

Open Curettage and Debridement

Open curettage and debridement is an open surgical procedure whereby the devitalized and injured articular cartilage is debrided back to a smooth and stable surface. Pridie²⁵ introduced the concept of drilling the subchondral bone with a 0.365-cm (0.25-in) drill to stimulate a fibrocartilagenous repair of a full-thickness chondral defect. Magnuson³³ believed that repetitive microtrauma was the major cause of

degenerative arthritis and that by surgically removing the rough and irritating edges one could produce "spectacular" results. Current advocates of open curettage and debridement cite pain relief and improved function as benefits of the procedure, possibly due to the role of enzymatic degradation in the evolution of the osteoarthritic process. Others believe that any therapeutic improvements are transient at best and do not justify the procedure.

Arthroscopic Lavage and Debridement

The use of arthroscopic lavage in the treatment of articular cartilage injuries was reported by Jackson.^{26,27} Arthroscopic lavage entails inserting arthroscopic instruments into the knee and irrigating the joint with sterile fluid. Jackson²⁷ observed that patients with intra-articular knee pathology benefited with significant pain relief following lavage alone. At 3.5 years postoperatively, 45% of patients continued to experience some pain relief, while 20% felt no improvement. When arthroscopic debridement was added to lavage, results were even better. In a follow-up study in 1988, Jackson²⁷ reported that 88% of 137 patients reported immediate clinical improvement after lavage, while 68% had continued improvement at 3 years.

Chang et al⁷ performed a prospective, randomized study investigating the results of arthroscopic lavage and debridement. They concluded that both arthroscopic lavage with debridement of loose bodies and closed needle joint lavage provide short-term symptomatic relief in patients with degenerative joint disease.

Hubbard²⁴ performed a prospective, randomized study of 76 knees to clarify the role of arthroscopic lavage versus debridement. The knees were radiographically normal, but had unipolar (defect found on only 1 side of the joint) chondral lesions, which were grade III or IV lesions, according to the Outerbridge classification. At a 4.5-year follow-up, debridement was decisively superior to lavage alone. At 1-year and 5-year follow-ups, Lysholm scores improved by 28 and 21, respectively, in the debridement group, compared to improvements of 5 and 4, respectively, in the lavage group.²⁴

The role of lavage is to remove loose intra-articular debris and inflammatory mediators known to be generated by the synovial lining of damaged joints. Via this mechanism, lavage improves tenderness and night pain in the immediate postoperative period and may provide some pain relief for up to 3 years. In contrast, joint debridement removes mechanical pathology and may provide measurable functional improvements for up to 5 years. Neither lavage nor debridement correct the underlying pathology in a degenerated joint. Thus, while these treatments may provide transient pain relief, they are generally inadequate for athletic or active patients.

Abrasion Arthroplasty

Abrasion arthroplasty was first popularized by Lanny Johnson.^{28,29} The premise underlying the potential success of this technique is that exposed sclerotic bone in the degenerative knee joint has a significant blood supply less than 1 mm below its surface. Superficial abrasion results in a fibrocartilagenous healing without extensive disruption of the integrity of the bone. However, an overly aggressive abrasion can violate the subchondral bone plate and destabilize the joint, resulting in the distortion of the mechanical axis. In the malaligned knee, intra-articular debridement or abrasion arthroplasty is not recommended as an isolated procedure in light of the altered biomechanical forces and the fact that the original hyaline cartilage deteriorated under these same forces.⁴²

Mechanism of Healing by Microfracture

The goal of the microfracture technique is to stimulate the underlying marrow, which, in turn, may lead to a stereotyped vascular response to injury. Following penetration of the subchondral plate, a biologic response is stimulated. This biologic response is divided into 3 distinct phases: necrosis, inflammation, and repair.³⁶ Necrosis begins immediately after injury and is characterized by varying degrees of tissue death, depending on the severity of the trauma and the adequacy of the blood supply. Necrosis is most obvious at the margins of the chondral defect. The inflammatory phase is mediated by the local vasculature. A reactive hyperemia and increase in capillary permeability leads to a transudation and cellular exudation which forms a dense fibrin network at the site of injury.³⁶ This network is rich in inflammatory cells, with the potential for cell division and the possibility for repair. This fibrin network becomes organized into a primitive glue. The repair phase begins when the fibrinous mass is invaded by neovascularization. A cascade of events then occurs. The inflammatory cells modulate into fibroblasts, which produce a loose granulation tissue. Ultimately, this matures into a fibrous repair matrix and finally a scar. In tissue such as bone callus and tendon, the repair phase is associated with replication of the damaged tissue type, rather than a simple collagen scar. The remodeling process then tries to recreate normal anatomy.

The body's response to a purely cartilaginous injury follows a slightly different pathway. The reason for this difference is that with a purely cartilaginous injury the subchondral plate is not penetrated. While cartilage undergoes the same necrotic phase as any other body tissue, the inflammatory phase is almost completely absent.³⁶ The processes of transudation, exudation, and hematoma formation are absent. Thus a fibrin clot does not exist to serve as a scaffold

for repair. With no new repair cells, the task of repair falls on the existing chondrocytes. While these cells are metabolically active, they are incapable of producing the required repair products. On the other hand, if the injury extends through the calcified zone into subchondral bone, all 3 phases of repair are stimulated. The underlying bone is an excellent source of new blood vessels and primitive cells for differentiation and modulation to fibroblasts or chondroblasts, which are required for repair.³⁶

Full-thickness articular chondral defects secondary to injury or drilling fill with blood and organize rapidly into a fibrous clot. Blood cells, undifferentiated bone-marrow elements, and platelets all combine in the defect.³⁵ The undifferentiated mesenchymal cells, often referred to as fibroblasts, may arise from the bone marrow, pannus, synovial membrane, or superficial zone of articular cartilage. This tissue is capable of differentiation into several types of tissue including fibrous tissue, bone, and synovial membrane.⁶ Depending on the anatomic location and the pre-existing condition, these cells may be capable of transformation into hyaline cartilage. This occurs in the margins of embryonic joints, areas of rapid cartilage growth in the immature animal, and in some cartilage tumors. In other situations, these undifferentiated cells can transform into fibrocartilage. This occurs in normal tissues of the growing animal and in many repair processes, such as callus formation, loose bodies, margins of pseudarthroses, margins of joints, and ectopic sites.⁶ Undifferentiated cells modulate into fibroblasts, which produce a reparative granulation tissue. By 10 days after the injury, there is progressive fibrosis that becomes less vascular and more sclerotic. The fibrous tissue undergoes a progressive hyalinization and chondrification to produce a fibrocartilagenous matrix that "heals" the defect, which is permanently marked by a pit or dimpled scar.³⁵ Left untreated, large chondral defects in the human fill with fibrous tissue and fibrocartilage, while small defects heal mostly with fibrocartilage or hyaline cartilage.⁶

In a study by Gill et al,¹⁷ the treatment of chondral defects with the microfracture technique had better results when the size of the lesion was less than 400 mm², showing a trend of less pain at final follow-up. This finding was also supported by Convery,⁹ who found in horses that defects less than 3 mm in diameter showed complete repair after 3 months, while defects larger than 9 mm failed to heal. This finding may be explained by the role played by chondrocytes in the adjacent articular surfaces in the healing of chondral defects.^{43,44} While these chondrocytes play no direct role in the repair, materials may diffuse from them into the repair tissue and subsequently lead to regulation of the differentiation along the chondroid line.¹⁵ Perhaps this diffusion

does not reach the central aspect of a large chondral defect, leading to the development of a fibrous-type tissue.

Mesenchymal Cell Differentiation

The ability of undifferentiated cells to transform into cartilage has been described. Connective tissue acting as interposition material undergoes metaplastic development into cartilage when under the influence of the pressure and function of the joint.³¹ Bennett and Bauer² report that repair tissue develops through stages of metaplasia, beginning with fibrous tissue that originally filled the defect and took its origin in the marrow spaces of the subchondral bone. Throughout their study, DePalma et al¹⁰ noted that the nature of the reparative process was not dependent on the skeletal maturity of the animals tested, supporting the concept of fibrous tissue metaplasia. The tissue begins as fibrin deposition, which then develops into granulation tissue and connective tissue. Finally, it gives rise to cartilage cells in connective tissue, fibrocartilage, and ultimately hyaline cartilage.

The response to injury in the human body differs, depending on the tissue that is damaged. The tissue of the skin, liver, and kidney repair with collagen scar. On the other hand, the tissue of bone, tendon, and synovium repair with like-tissue.³⁶ Regardless of the type of tissue involved, all tissue repair relies on a cellular process in which fibroblasts or specialized cells synthesize the repair material. The new cells evolve by cell replication, modulation of existing cells, or migration of cells from the wound or from blood vessels entering the tissue.³⁶ Techniques such as microfracture, drilling, and abrasion cause penetration of the subchondral plate, which allows blood supply to enter the chondral defect and provides the necessary material for extrinsic repair.⁴² Without penetration of subchondral bone, the absence of an intrinsic vascular system prohibits an injury to the articular cartilage from inciting the commonly observed inflammatory response.³⁵

The timing of this sequence of events has been studied in a rabbit model.¹⁵ Deep chondral lesions filled with granulation tissue. The fibroblasts differentiated into chondrocytes by 7 to 10 days after the injury. By 3 weeks after the injury, type I collagen was the primary collagen in the repair tissue. By 6 to 8 weeks after the injury, type II predominated by radiochemical analysis. It is interesting to note that the quality of the cartilage continued to improve up to 1 year.¹⁵ Because type I collagen still persisted, the repair tissue never fully resembled normal articular cartilage.

In full-thickness defects of weight-bearing areas in dogs, blood elements and clot formation are present by 2 days after surgery.¹⁰ At 1 week, spindle-shaped cells are abundant. At 4 weeks, the clot appears

yellowish in color and is depressed below the articular surface. New vascular channels have formed. The spindle-shaped cells are more round with an increase in cytoplasm. By 8 weeks, the defect is filled with a highly cellular immature chondroid that is glossy white and has the appearance of the surrounding cartilage. By 16 weeks, the repair tissue blends with the surrounding edges of the defect. At 32 and 66 weeks, the full-thickness defects are obliterated by tissue that appears both grossly and histologically to be articular cartilage.¹⁰

Effect of the Local Environment on Chondral Healing

The effect of the local environment on the differentiation of periosteal cells has been studied.^{45,48} Perichondral grafts have the capacity to generate cartilage. However, the differentiation of these cells into hyaline cartilage depends on extrinsic environmental factors.¹ Likewise, the differentiation of the cells of the cambium layer of the periosteum depends on environmental conditions.⁴⁷

High oxygen tension has been shown to stimulate bone formation, while low oxygen pressure results in cartilage formation.⁴⁷ When too much cancellous bone in a chondral defect is removed, there is an increase in vascularization that leads to higher oxygen tension. This, in turn, results in enchondral ossification. A strong osteogenic stimulus from the cancellous bone may also favor ossification.⁴⁷ For these reasons, the subchondral bone is generally not abraded during microfracture. In addition to stimulating ossification, subchondral abrasion could also destabilize the bony architecture and lead to angular deformities over time. This could lead to increased compartmental pressure, which could stimulate the repair tissue to differentiate more rapidly into fibrous tissue to try and protect the joint surface.

Removal of the calcified cartilage layer can greatly enhance the potential to fill the defect.^{13,14,39} By removing the calcified cartilage, there is a better scaffold for the "superclot" to adhere to. In addition, nutrition of the chondral surface is improved through subchondral diffusion. The calcified zone is separated from the tangential, transitional, and radial zones by the tidemark. In the immature animal, the basal layers of cartilage receive a portion of their nourishment via diffusion from the vasculature of the subchondral bone. In the adult, there is heavy deposition of apatites in the calcified zone, which prevents diffusion of nutrients across the tidemark.^{34,35} The calcified zone also functions as an efficient barrier to cellular invasion. This may explain the apparent immunity of cartilage transplants to the allograft rejection process.³ Thus, by removing the calcified zone, there may be an enhanced scaffold for adhesion of the fibrin clot, as well as an improvement

in the nutrition of the repair tissue by expediting the diffusion of nutrients from the subchondral circulation.

Effect of Weight-Bearing and Motion on Cartilage Differentiation

The postoperative protocol of continuous passive motion (CPM) and protected weight bearing for 8 weeks is based on multiple experimental studies examining the influence of motion and mechanical stress on the differentiation of mesenchymal repair cells. Johnson^{28,29} suggests that weight bearing or joint loading delays healing of both partial and full-thickness defects. Up to 2 months of non-weight bearing may be required to promote early fibrous tissue maturation.

The beneficial effect of motion on the healing of articular cartilage injuries is well documented.^{1,40,46,50,51} The use of CPM enhances nutrition and metabolic activity of the articular cartilage. In addition, CPM may stimulate the pluripotential mesenchymal cells to differentiate into articular cartilage rather than fibrous tissue or bone. Finally, CPM may accelerate the healing of both articular cartilage and periarticular tissues.⁵⁰

In grafts that are exposed to CPM there is consistent evidence of differentiation along a chondroid line within 2 weeks.⁴⁰ In animals whose articular function was preserved, cartilage metaplasia was observed 3 weeks postoperatively in the connective tissue that was filling the defect. Embryonal type cells were found in the repair tissue adjacent to the articular surface. The flow of matrix from the surrounding articular surface may influence this metaplasia. This flow of matrix may be dependent on pressure exerted on the articular surfaces. In animals lacking articular function, no matrix flow was observed. Presumably, this is due to the necrotic cartilaginous zone at the margins of the defects.³⁰ The metaplasia of the repair tissue from undifferentiated mesenchymal tissue to hyaline articular cartilage was much more rapid and complete in defects exposed to CPM rather than immobilization or intermittent motion.

The destructive effect of immobilization on joint function is also well known. The immobilization of a joint leads to a flattening of the articular surface.²¹ Noncontact areas undergo significant degeneration. Immobilization for 3 weeks had an inhibitory effect on chondrogenesis, which was even more pronounced after 6 weeks.⁴⁹ Chondrogenesis partially recovered after the initiation of mobilization. After immobilizing the elbow joint of rabbits after surgery, Haldeman²⁰ noted numerous intra-articular adhesions with no repair of the traumatized articular surface. On the other hand, Hohl and Luck^{22,23} observed that with early mobilization, the chondral

defects filled with connective tissue, which gradually turned into cartilage. The functional mobilization of the joint was essential to such a transformation.

Synovial fluid is a source of nutrition for cartilage proliferation and it may also contain chondrotrophic properties.^{47,48} The cyclical pumping action of the CPM enhances the delivery of nutrients to the articular cartilage.^{12,42} In addition, physiological exercise increases the volume of synovial fluid. On the other hand, immobilized joints have less synovial fluid for nutrition.⁴⁹ The presence of motion and the absence of vascularity from the synovial fluid maximizes chondrogenesis. In addition, hemarthrosis is cleared more than twice as fast with the use of a CPM.⁵⁰ This may lower the oxygen tension around the defect, which favors the formation of cartilage.

Indications for Microfracture

The indications for microfracture have been reported by Gill et al.¹⁶ The microfracture technique may be useful for both focal traumatic chondral defects as well as degenerative lesions. This differentiates microfracture from “cell-based” or “biologic” treatments. Furthermore, microfracture is not limited to unipolar defects. Unipolar defects are lesions that are found on only 1 side of the joint (either the femoral condyle or tibial plateau). Microfracture can be used in the presence of bipolar or “kissing” lesions. Bipolar lesions are found on both sides of the joint at adjacent locations.

The microfracture technique is safe, technically straightforward, and has an extremely low rate of associated patient morbidity. Thus, it is very useful as a first-line of treatment for almost all focal, traumatic chondral defects in the knee, regardless of location or size. In the author's review of over 100 patients with full-thickness, focal defects treated by microfracture by Dr Richard Steadman, the defect location and size did not reveal a statistical difference in the patient's clinical outcome.¹⁷ Another advantage of the microfracture technique is that it does not burn any bridges with regard to future surgical procedures should the microfracture fail.

The microfracture technique has several other advantages over other surgical treatments for chondral defects in the knee. Initial reports on autologous chondrocyte transplantation demonstrated inferior results in the patellofemoral joint, although these inferior results may be related to patellar maltracking.² Techniques such as osteoarticular transplantation might have limited indications for larger lesions due to the potential for graft site morbidity. Such techniques also limit the availability of potential future surgical options in the event of initial clinical failure.

Contraindications

Contraindications to the microfracture technique may be thought of as relative rather than absolute. While there is no statistically significant difference in the outcome of microfracture based on size alone, lesions less than 400 mm² tend to have less postoperative pain than larger lesions.¹⁷ In the setting of a larger lesion (greater than 3 cm diameter), second-look arthroscopy may be helpful following microfracture. If healing is judged to be incomplete when evaluated arthroscopically, a repeat microfracture to the unhealed areas can be performed, or a different resurfacing technique can be considered.

The amount of time elapsed from the date of injury is also a consideration in the treatment of chondral defects. Lesions treated by microfracture within 12 weeks of injury have significantly better outcomes than more chronic lesions. However, even degenerative lesions can have excellent outcomes following microfracture.

Another important consideration in determining the appropriate treatment of a chondral defect in the knee is the location of the lesion. While there is no statistical difference in the outcome of microfracture based purely on the location in the knee, femoral and trochlear lesions seem to have a more predictable “fill” than tibial or patellar lesions. This seems particularly important when the microfracture is performed on an arthritic knee. The author’s personal experience with second-look arthroscopy following microfracture of the medial compartment done in conjunction with a high tibial osteotomy typically reveals a good healing response on medial femoral condyle, but more patchy coverage on the tibial plateau. This finding may be secondary to the dense, sclerotic bone present in the plateau in the setting of varus gonarthrosis.

Microfracture as a solitary procedure has limited indications for lesions with a depth greater than 5 mm, and should generally not be used for defects over 10 mm deep. Deep lesions must be evaluated individually in order to choose the appropriate procedure. In these situations, the author would typically debride and bone graft the defects. Depending on the size and location of the lesion, a mosaicplasty or autologous chondrocyte transplantation may be preferred. Osteochondritis dissecans is not an absolute contraindication to the microfracture technique unless marrow bleeding cannot be produced from the base of the defect after debridement, or the depth of the lesion is greater than 10 mm.

The most significant contraindication to the microfracture technique is a malaligned knee. While there are no specific criteria regarding the degree of deformity, any attempt at resurfacing the medial compartment in the setting of varus alignment will

almost routinely fail because the stress pattern of the underlying pathologic malalignment will continue to destroy the medial compartment. In this situation, a microfracture should be performed in conjunction with a high tibial osteotomy to re-establish a neutral mechanical axis. Similarly, lateral patellofemoral chondral lesions have a worse prognosis in the setting of patellar maltracking. In this situation, consideration should be given to correcting the patellar-tracking problem at the same time as the chondral injury is treated.

Microfracture Surgical Technique

The technique of microfracture has previously been reported.¹⁶⁻¹⁸ A routine diagnostic arthroscopy is used to evaluate all intra-articular compartments of the knee. Prior to performing the microfracture, any associated intra-articular pathology (such as a meniscal tear) is addressed. The surgeon must pay careful attention when examining the posterior aspects of the medial and lateral femoral condyles. If any damage is noted on the articular surfaces, a probe is used to assess the quality of the cartilage. Any unstable flaps are sharply debrided using an arthroscopic shaver or curette. Next, a curette is used to debride the calcified cartilage layer from the base of the full-thickness defect (Figure 1). This step is based on the work of Frisbie et al,¹⁴ who demonstrated superior articular surface repair in a horse model when the calcified cartilage layer is removed. When debriding the calcified cartilage layer, an arthroscopic shaver is generally not used. With a shaver, it is difficult to control the amount of bone removed, and the subchondral bone is more likely to be violated.

After successful debridement of the calcified cartilage layer, a surgical awl is used to make multiple small holes (“microfractures”) in the exposed bone of the chondral defect spaced 1 to 2 mm apart (Figure 2). Care is taken to leave an adequate bone bridge between the holes. The microfracture technique has several advantages over drilling. First of all, it creates less thermal injury than drilling. Furthermore, with microfracture, the surgeon is able to access difficult areas of the articular surface with better control over the depth of penetration. Upon completion of the microfracture, a rough surface is generated for adherence of the blood clot containing the undifferentiated mesenchymal cells from the subchondral bone. Care should be taken to ensure that the most peripheral aspects of the lesion are penetrated by the awl to aid in the healing of the repair tissue to the surrounding articular surface. Once the microfracture is complete, the arthroscopic pump is turned off to make sure that marrow bleeding is observed flowing from the small holes and filling the defect (Figure 3).

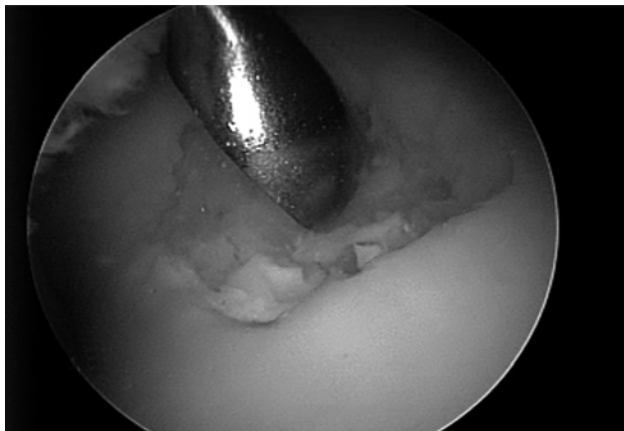

FIGURE 1. A curette is used to debride the calcified cartilage layer from the base of the defect.

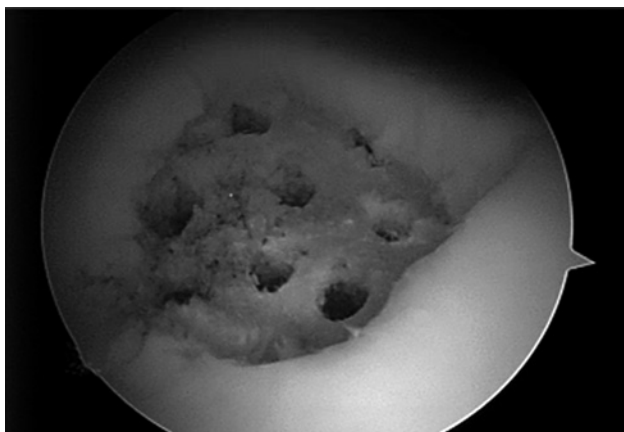


FIGURE 2. A surgical awl is used to create multiple small holes in the bone, spaced 1 to 2 mm apart.

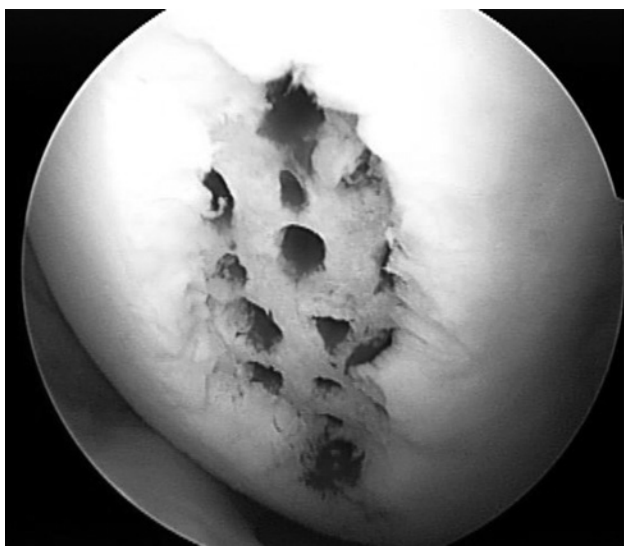


FIGURE 3. After completion of the microfracture, the arthroscopic pump is turned off to confirm adequate bleeding from each hole.

Postoperative Rehabilitation Following Microfracture

With regard to the microfracture technique, postoperative management may be as important as the

actual surgery. This management must be based on the biology of articular cartilage repair and not simply on “clinical impression.” The extent of chondral defect healing and the time course associated with the healing process after microfracture in humans are not well described. Most surgeons recommend a period of restricted weight bearing after microfracture to protect the healing cartilage. However, there is limited data available to help to guide the physician with decisions regarding the duration of such restrictions. Recently, Gill et al¹⁹ studied the healing of chondral defects in a nonhuman primate model. Full-thickness chondral defects were created on the femoral condyles and trochlea of 12 cynomolgus macaques and treated with microfracture.¹⁹ Subsequently, these defects were evaluated by gross and histologic examination at 6 and 12 weeks postoperatively in order to gain more objective evidence on which to make weight-bearing recommendations. At 6 weeks postoperatively, there was limited chondral repair with ongoing resorption of subchondral bone. By 12 weeks postoperatively, the defects were completely filled and showed more mature cartilage and bone repair. The poor status of the defect repair at 6 weeks and the ongoing healing observed from 6 to 12 weeks postoperatively may indicate that the repair is vulnerable during this initial postoperative period. Assuming that the goal of restricted, postoperative weight bearing in patients after microfracture is to protect immature repair tissue, this study suggests that weight-bearing restrictions should be in place for longer than 6 weeks. In addition, it is the author’s common practice to send these patients home with a CPM machine for 8 weeks.

The actual postoperative weight-bearing status depends on the location of the chondral lesion within the knee. Lesions involving the articular surface of the patella and trochlear groove may be weight-bearing as tolerated in a hinged brace, with a 30° flexion stop. Because the patella does not engage the trochlear groove until after 30° of flexion, this specific protocol prevents excessive pressure in the patellofemoral joint. Patients are instructed to remove their brace when they are not weight bearing, at which time they use a CPM machine from 10° to 90° for at least 8 hours per day. If for some reason a CPM machine is not available, then the patient is instructed to move the knee passively in flexion-extension, while sitting at the edge of a table, 1500 times per day.

If the chondral defect is located in the medial or lateral compartment of the knee, the patient is kept strictly touch-down weight bearing (15% weight bearing) for the first 6 weeks after surgery. The CPM machine is set at 1 cycle per minute, using the largest range of motion that the patient finds comfortable. If the lesion is located in a non-weight-bearing region

of the medial or lateral compartment, weight bearing may begin as early as 6 weeks postoperatively, depending on the size of the defect. Following the initial 6-week period of protected weight bearing, patients are allowed to begin active range-of-motion exercises and to progress to full weight bearing as tolerated. Return to sports, which requires cutting, twisting, or jumping, is restricted until at least 4 months postoperatively.

Results of Microfracture for Traumatic Chondral Defects

The results of microfracture for traumatic chondral defects has been reported. Over 100 patients who underwent a microfracture for a full-thickness chondral defect were evaluated.¹⁷ The average follow-up was 6 years. Using a scoring system designed specifically for the treatment of chondral defects, patients were objectively assessed based on their preoperative and postoperative examinations. Microfracture resulted in a statistically significant improvement ($P < .05$) in pain, swelling, and all other functional parameters studied. The patients' ability to walk 2 miles and descend stairs also demonstrated significant improvement. The patients' ability to perform activities of daily living, strenuous work, and sports also improved significantly. Improvement in symptoms of pain and swelling continued until 2 years postoperatively. In addition, maximum functional improvement was not achieved until 2 to 3 years postoperatively. Eighty-six percent of patients rated their knee as feeling normal to nearly normal following their microfracture procedure. Only 14% of patients noted a decrease in their level of sports participation following microfracture.¹⁷

In terms of the location of the chondral lesion, there was no statistically significant difference in outcome between patellofemoral lesions and lesions in the medial or lateral compartment. Larger lesions tended to have more pain at final follow-up than smaller lesions; however, this difference was not statistically significant. Regardless of the lesion size, chondral defects treated within 3 months of injury had significantly less pain and better functional scores for their activities of daily living than lesions treated after this 3-month time point.¹⁷

Gill and MacGillivray¹⁸ reported on 19 patients with isolated defects of the medial femoral condyle treated with microfracture. The average size of the defects was 3.2 cm². At an average follow-up of 3 years, 74% of patients reported minimal or no pain. Using the Cincinnati scoring system, 63% of patients had good to excellent results. In this series, the calcified cartilage layer was not routinely debrided. Postoperative radiographic analysis using MRI demonstrated that the defect was 67% to 100% filled in 42%

of patients, 31% to 66% filled in 21% of patients, and 0% to 30% filled in 37% of patients.¹⁸

The long-term results of microfracture for isolated chondral defects in the knee were more recently reported by Steadman et al.⁵² A series of 72 patients (75 knees) under the age of 45 years with traumatic full-thickness chondral defects were studied.⁵² These patients had no associated meniscus or ligament injury. Significant improvement was recorded using both Lysholm scores (preoperative, 59; final follow-up, 89) and Tegner scores (preoperative, 3; final follow-up, 6). At 7 years postoperatively, 80% of the patients rated themselves as "improved." Using a multivariate analysis, it was revealed that age was a predictor of functional improvement. At an average follow-up of 11.3 years, patients 45 years and younger who underwent the microfracture procedure for full-thickness chondral defects demonstrated statistically significant improvement in function and indicated that they had less pain.⁵²

Results of Microfracture in Osteoarthritic Knees

Miller et al³⁷ studied the use of microfracture in 81 patients over the age of 40 years (range, 40-70 years). The average size of the lesions was 229.5 mm² (range, 25-2000 mm²).³⁷ Both the Lysholm and Tegner scoring systems were used as objective assessments of the long-term clinical results. There was a significant improvement in outcome with regard to subjective complaints of pain and swelling when compared to preoperative scores. The Lysholm score improved from 53.8 to 83.1, while the Tegner Activity scores improved from 2.9 to 4.5. The location of the defect in the knee had no clinical correlation to the outcome. Five patients (5.9%) required either a revision microfracture or total knee replacement at an average of 23 months postoperatively (range, 5-36 months). Thirteen patients (15.5%) required repeat arthroscopy within 5 years of the initial procedure.³⁷

It is important to try to establish preoperatively which patients will benefit from a microfracture. It is our experience that predictors for a poor result following microfracture include the presence of a chronic lesion, bipolar or kissing lesions, and large sclerotic lesions. In addition, the severity of preoperative joint space narrowing and the presence of knee malalignment play a significant role in outcome following microfracture.

Durability of Repair Following Microfracture

It is generally accepted that penetration of the subchondral plate can result in healing of a full-thickness defect (Figure 4). However, the quality and longevity of the repair tissue that develops has been a source of debate. Mitchell and Shepard³⁸ demonstrated in a rabbit model that the primary fibrous

repair tissue was converted to a hyaline-like chondroid tissue with an increasing concentration of proteoglycan. By 12 months after injury, the original defect looked less like hyaline cartilage and appeared to be filled with more fibrous or fibrocartilagenous tissue. Furthermore, the tangential collagen layers were absent. Subsequently, fibrillation of the surface was noted and the defect became more collagenous. The clinical finding that the repair tissue found after microfracture ultimately degenerates and results in a localized form of osteoarthritis has been shown in the lab as well.³⁵ On the other hand, other experimental studies have concluded that a high-quality repair can result from penetration of subchondral bone. While the repair tissue does show a decrease in hexosamine content and in galactosamine-glucosamine ratios, there is a shift from type I to type II collagen within 5 to 6 weeks after surgery.⁸ The ultimate repair tissue closely resembles hyaline cartilage with diminished proteoglycan. This tissue still retains up to 20% type I collagen,¹⁵ suggesting that it is a mixture of fibrocartilage and hyaline cartilage. Salter^{50,51} has demonstrated that the percentage of fibrocartilage present in the repair tissue can be decreased with the use of CPM.

Gill et al¹⁷ have reported on a series of 40 second-look arthroscopies in their series of long-term results following microfracture. These second-look arthroscopies were performed on patients with new injuries or continued pain. In half of the knees that underwent microfracture, a firm, well-fixed, normal appearing cartilaginous tissue had completely filled the site of the previous defect. In 16% of the patients studied, a mildly fibrillated or discolored cartilaginous-appearing tissue was found at the site of the previous defect. In 18% of the patients studied, the defect was completely filled, but uneven or slightly fragmented. In 16% of the patients studied, the defects had at least 1 area of exposed bone at their base.

CONCLUSIONS

The potential for articular cartilage to heal depends on several conditions. It is essential to have a source of cells, provision of a matrix, removal of stress across the joint, and an intact subchondral plate.⁴² The clinical results and second-look arthroscopies performed by Gill et al^{18,19} confirm that it is possible to generate durable repair tissue using the microfracture technique.

There are 5 principal factors that affect the quality of the cartilaginous repair tissue in a full-thickness chondral defect treated by microfracture. (1) During the debridement of the defect, the calcified cartilage layer must be removed; however, the surgeon must also be careful not to significantly abrade the subchondral bone. (2) The subchondral bone must be penetrated by the awl leaving a 1- to 2-mm bone

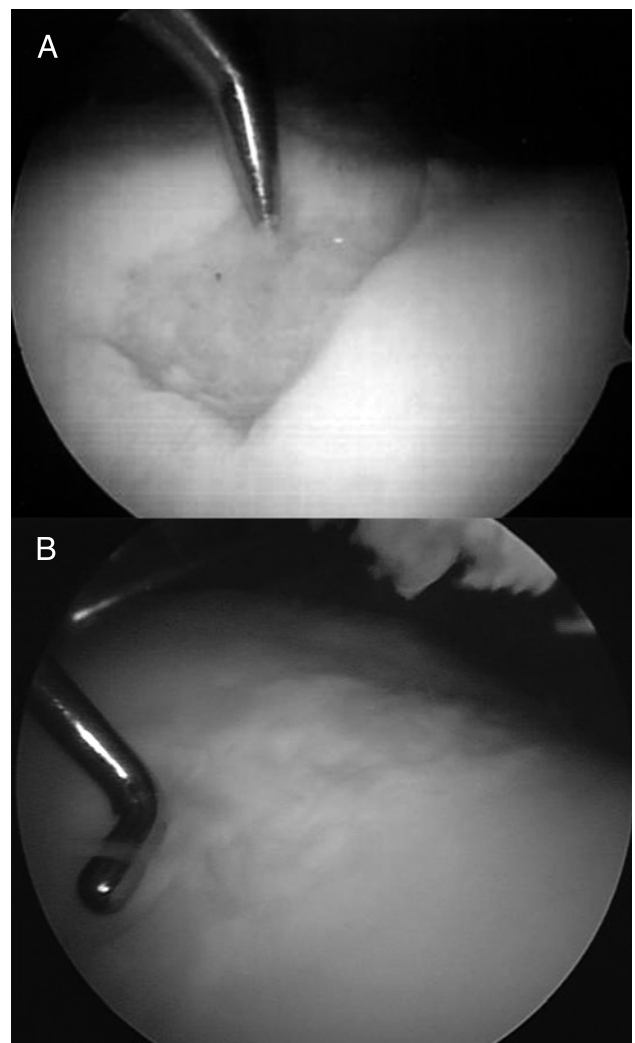


FIGURE 4. (A) Arthroscopic image of a trochlear chondral defect in a 31-year-old female athlete undergoing microfracture. (B) Second-look arthroscopy of the same patient 1.5-year status post microfracture. The patient was asymptomatic from this lesion.

bridge between holes to allow connective tissue to fill the defect and adhere to the base of the defect. (3) Postoperative articular function must be maintained by the use of early continuous passive motion. (4) Protected weight bearing must be strictly enforced, depending on the location of the lesion. (5) Any significant abnormality in the mechanical axis should be corrected in conjunction with the microfracture, especially for degenerative lesions. All of these factors are essential for a high-quality cartilaginous metaplasia to occur.

The microfracture technique is a cost-effective, technically feasible, and highly efficacious procedure available to all surgeons who perform arthroscopy of the knee. The microfracture technique is a reasonable first-line approach to the treatment of full-thickness chondral defects. This technique does not burn any bridges with regard to future procedures such as a mosaicplasty or an autologous chondrocyte transplant as a second procedure should the microfracture fail. In the future, modification of the

cellular differentiation following microfracture with exogenous growth factors and/or scaffolds may serve to improve the quality of the repair tissue generated in the defect, which would further maximize long-term outcomes.

REFERENCES

1. Amiel D, Coutts RD, Abel M, Stewart W, Harwood F, Akeson WH. Rib perichondrial grafts for the repair of full-thickness articular-cartilage defects. A morphological and biochemical study in rabbits. *J Bone Joint Surg Am.* 1985;67:911-920.
2. Bennett GA, Bauer W. A study of the repair of articular cartilage and the reaction of normal joints of adult dogs to surgically created defects of articular cartilage, joint mice and patellar displacement. *Amer J Path.* 1932;8:499-523.
3. Brown KL, Cruess RL. Bone and cartilage transplantation in orthopaedic surgery. A review. *J Bone Joint Surg Am.* 1982;64:270-279.
4. Buckwalter JA. Articular cartilage matrix. AAOS Instructional Course Lectures. Rosemont, IL: American Association of Orthopaedic Surgeons; 1988.
5. Calandruccio RA, Gilmer WS. Proliferation, regeneration, and repair of articular cartilage of immature animals. *J Bone Joint Surg Am.* 1962;44A:431-455.
6. Campbell CJ. The healing of cartilage defects. *Clin Orthop Relat Res.* 1969;64:45-63.
7. Chang RW, Falconer J, Stulberg SD, Arnold WJ, Manheim LM, Dyer AR. A randomized, controlled trial of arthroscopic surgery versus closed-needle joint lavage for patients with osteoarthritis of the knee. *Arthritis Rheum.* 1993;36:289-296.
8. Cheung HS, Cottrell WH, Stephenson K, Nimni ME. In vitro collagen biosynthesis in healing and normal rabbit articular cartilage. *J Bone Joint Surg Am.* 1978;60:1076-1081.
9. Convery FR, Akeson WH, Keown GH. The repair of large osteochondral defects. An experimental study in horses. *Clin Orthop Relat Res.* 1972;82:253-262.
10. DePalma AF, McKeever CD, Subin DK. Process of repair of articular cartilage demonstrated by histology and autoradiography with tritiated thymidine. *Clin Orthop Relat Res.* 1966;48:229-242.
11. Eichelberger L, Akeson WH, Roma M. Biochemical studies of articular cartilage. I. Normal values. *J Bone Joint Surg Am.* 1958;40-A:142-152.
12. Frank C, Akeson WH, Woo SL, Amiel D, Coutts RD. Physiology and therapeutic value of passive joint motion. *Clin Orthop Relat Res.* 1984;113-125.
13. Frisbie DD, Oxford JT, Southwood L, et al. Early events in cartilage repair after subchondral bone microfracture. *Clin Orthop Relat Res.* 2003;215-227.
14. Frisbie DD, Trotter GW, Powers BE, et al. Arthroscopic subchondral bone plate microfracture technique augments healing of large chondral defects in the radial carpal bone and medial femoral condyle of horses. *Vet Surg.* 1999;28:242-255.
15. Furukawa T, Eyre DR, Koide S, Glimcher MJ. Biochemical studies on repair cartilage resurfacing experimental defects in the rabbit knee. *J Bone Joint Surg Am.* 1980;62:79-89.
16. Gill TJ. The role of the microfracture technique in the treatment of full-thickness chondral injuries. *Oper Tech Sports Med.* 2000;8:138-140.
17. Gill TJ. The treatment of articular cartilage defects using microfracture and debridement. *Am J Knee Surg.* 2000;13:33-40.
18. Gill TJ, MacGillivray JD. The technique of microfracture for the treatment of articular cartilage defects in the knee. *Oper Tech Orthop.* 2001;11:105-107.
19. Gill TJ, McCulloch PC, Glasson SS, Blanchet T, Morris EA. Chondral defect repair after the microfracture procedure: a nonhuman primate model. *Am J Sports Med.* 2005;33:680-685.
20. Haldeman KO. The healing of joint fractures. *J Bone Joint Surg Am.* 1938;20:912.
21. Hall MC. Cartilage changes after experimental immobilization of the knee joint of the young rat. *J Bone Joint Surg Am.* 1963;45-A:36-44.
22. Hohl M, Luck JV. Fractures of the tibial condyle; a clinical and experimental study. *J Bone Joint Surg Am.* 1956;38-A:1001-1018.
23. Hohl M, Luck JV. Tibial condylar fractures: a clinical and experimental study. *J Bone Joint Surg Am.* 1955;37:641.
24. Hubbard MJ. Articular debridement versus washout for degeneration of the medial femoral condyle. A five-year study. *J Bone Joint Surg Br.* 1996;78:217-219.
25. Insall J. The Pridie debridement operation for osteoarthritis of the knee. *Clin Orthop Relat Res.* 1974;61-67.
26. Jackson RW. *Arthroscopic Treatment of Degenerative Arthritis.* New York, NY: Raven Press; 1991.
27. Jackson RW, Marans HJ, Silver RS. Arthroscopic treatment of degenerative arthritis of the knee. *J Bone Joint Surg Br.* 1988;70-B:332.
28. Johnson LL. Arthroscopic abrasion arthroplasty historical and pathologic perspective: present status. *Arthroscopy.* 1986;2:54-69.
29. Johnson LL. Arthroscopic abrasion arthroplasty: a review. *Clin Orthop Relat Res.* 2001;S306-317.
30. Kettunen K. Effect of Articular Function on the Repair of a Full-Thickness Defect of the Joint Cartilage. An Experimental Study of Mature Rats. *Ann Chir Gynaecol Fenn.* 1963;52:627-642.
31. Kettunen KO. Skin arthroplasty in the light of animal experiments with special reference to functional metaplasia of connective tissue. *Acta Orthop Scand Suppl.* 1958;29:1-75.
32. Lipschitz H, Glimcher MJ. In vitro studies of the wear of articular cartilage: part II. *Wear.* 1979;52:297.
33. Magnuson PB. The classic: Joint debridement: surgical treatment of degenerative arthritis. *Clin Orthop Relat Res.* 1974;4-12.
34. Mankin HJ. The articular cartilages: a review. AAOS Instructional Course Lectures. Rosemont, IL: American Association of Orthopaedic Surgeons; 1969.
35. Mankin HJ. The reaction of articular cartilage to injury and osteoarthritis (first of two parts). *N Engl J Med.* 1974;291:1285-1292.
36. Mankin HJ. The response of articular cartilage to mechanical injury. *J Bone Joint Surg Am.* 1982;64:460-466.
37. Miller BS, Steadman JR, Briggs KK, Rodrigo JJ, Rodkey WG. Patient satisfaction and outcome after microfracture of the degenerative knee. *J Knee Surg.* 2004;17:13-17.
38. Mitchell N, Shepard N. The resurfacing of adult rabbit articular cartilage by multiple perforations through the subchondral bone. *J Bone Joint Surg Am.* 1976;58:230-233.

39. Norrdin RW, Kawcak CE, Capwell BA, McIlwraith CW. Calcified cartilage morphometry and its relation to subchondral bone remodeling in equine arthrosis. *Bone*. 1999;24:109-114.
40. O'Driscoll SW, Salter RB. The induction of neochondrogenesis in free intra-articular periosteal autografts under the influence of continuous passive motion. An experimental investigation in the rabbit. *J Bone Joint Surg Am*. 1984;66:1248-1257.
41. Paget J. The classics. II. Healing of cartilage. Sir James Paget, Bart, M.D., London, member of the RYAL Society. *Clin Orthop Relat Res*. 1969;64:7-8.
42. Rand JA. Arthroscopy and articular cartilage defects. *Contemp Orthop*. 1985;11:13-30.
43. Redfern P. The classics. 1. On the healing of wounds in articular cartilage. *Clin Orthop Relat Res*. 1969;64:4-6.
44. Redfern P. On the healing of wounds in articular cartilage. *Mont J Med Sci*. 1851;13:201-203.
45. Ritsila VA, Santavirta S, Alhopuro S, et al. Periosteal and perichondral grafting in reconstructive surgery. *Clin Orthop Relat Res*. 1994;259-265.
46. Rodrigo J, Steadman JR. Improvement of full-thickness chondral defect healing in the human knee after debridement and microfracture using continuous passive motion. *Am J Knee Surg*. 1994;7:109-116.
47. Rubak JM. Reconstruction of articular cartilage defects with free periosteal grafts. An experimental study. *Acta Orthop Scand*. 1982;53:175-180.
48. Rubak JM, Poussa M, Ritsila V. Chondrogenesis in repair of articular cartilage defects by free periosteal grafts in rabbits. *Acta Orthop Scand*. 1982;53:181-186.
49. Rubak JM, Poussa M, Ritsila V. Effects of joint motion on the repair of articular cartilage with free periosteal grafts. *Acta Orthop Scand*. 1982;53:187-191.
50. Salter RB. The biologic concept of continuous passive motion of synovial joints. The first 18 years of basic research and its clinical application. *Clin Orthop Relat Res*. 1989;12-25.
51. Salter RB, Simmonds DF, Malcolm BW, Rumble EJ, MacMichael D, Clements ND. The biological effect of continuous passive motion on the healing of full-thickness defects in articular cartilage. An experimental investigation in the rabbit. *J Bone Joint Surg Am*. 1980;62:1232-1251.
52. Steadman JR, Briggs KK, Rodrigo JJ, Kocher MS, Gill TJ, Rodkey WG. Outcomes of microfracture for traumatic chondral defects of the knee: average 11-year follow-up. *Arthroscopy*. 2003;19:477-484.
53. Thompson RC, Jr. An experimental study of surface injury to articular cartilage and enzyme responses within the joint. *Clin Orthop Relat Res*. 1975;239-248.